

بِسْمِ اللّٰهِ الرَّحْمٰنِ الرَّحِیْمِ

In the name of God, the Most Compassionate, the Most Merciful



Sonographic Developmental Milestones of the Fetal Cerebral Cortex

Sonographic Developmental Milestones of the Fetal Cerebral Cortex

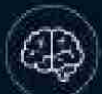

Vajiheh Marsoosi, M.D
Professor of Tehran University of Medical Sciences
Shariati Hospital

A remarkable thought



The cortex is biology becoming thought



Memory



Poem



Dream

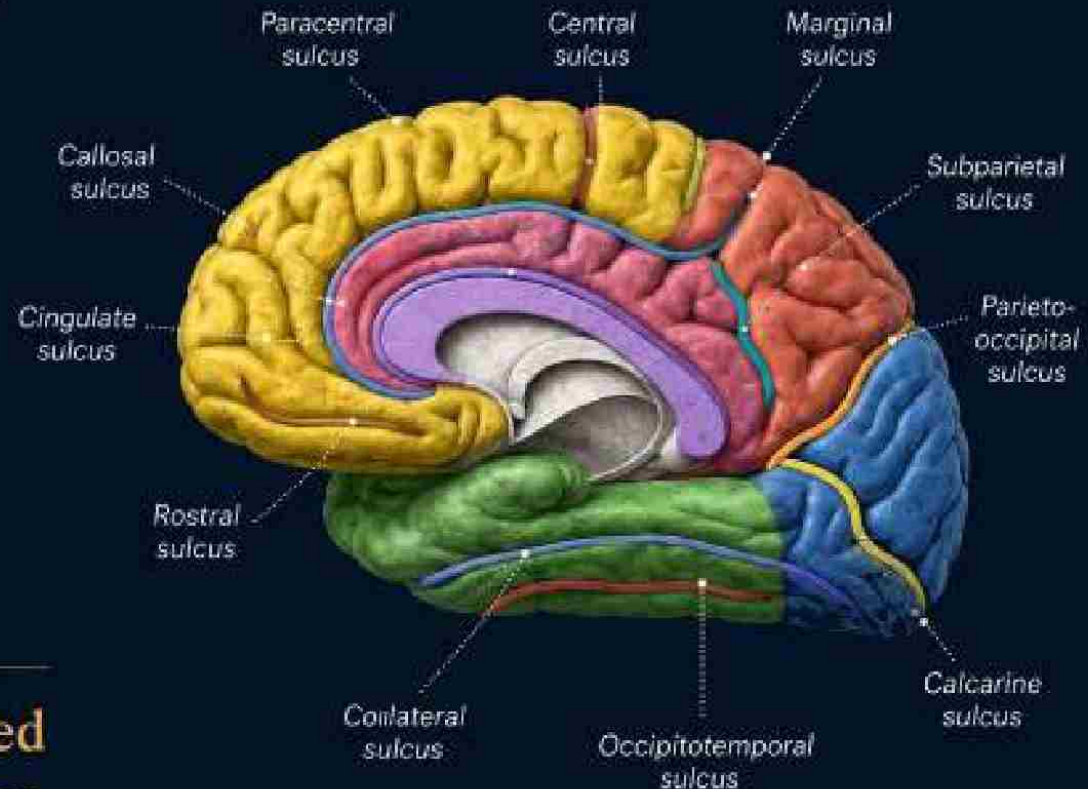


Mathematical proof



Act of kindness

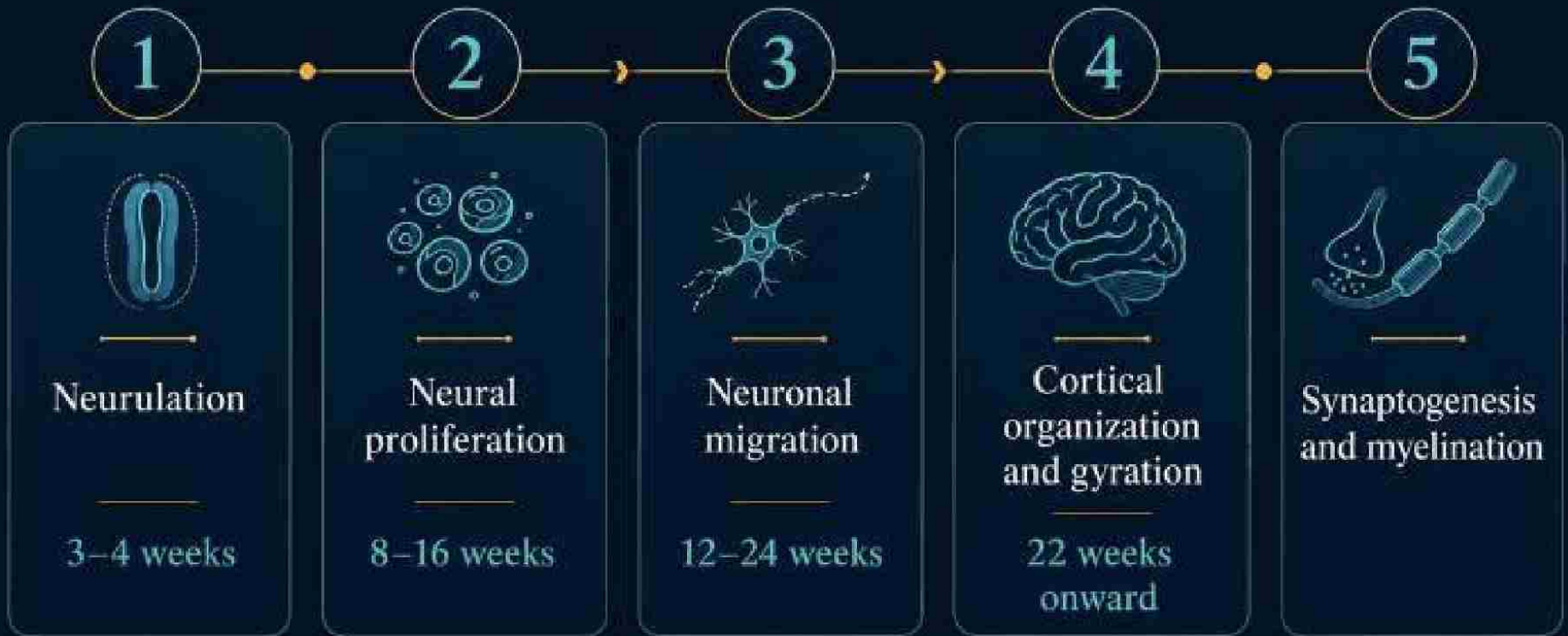
SULCI OF THE BRAIN



All are ultimately represented by patterns of activity across cortical networks.

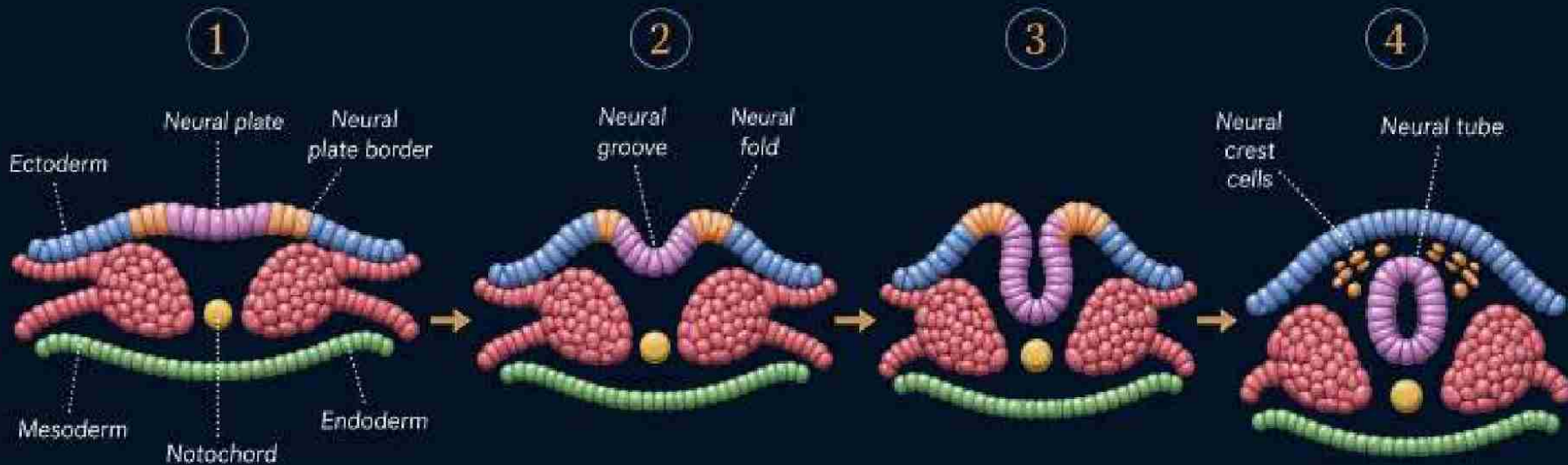


Main developmental stages



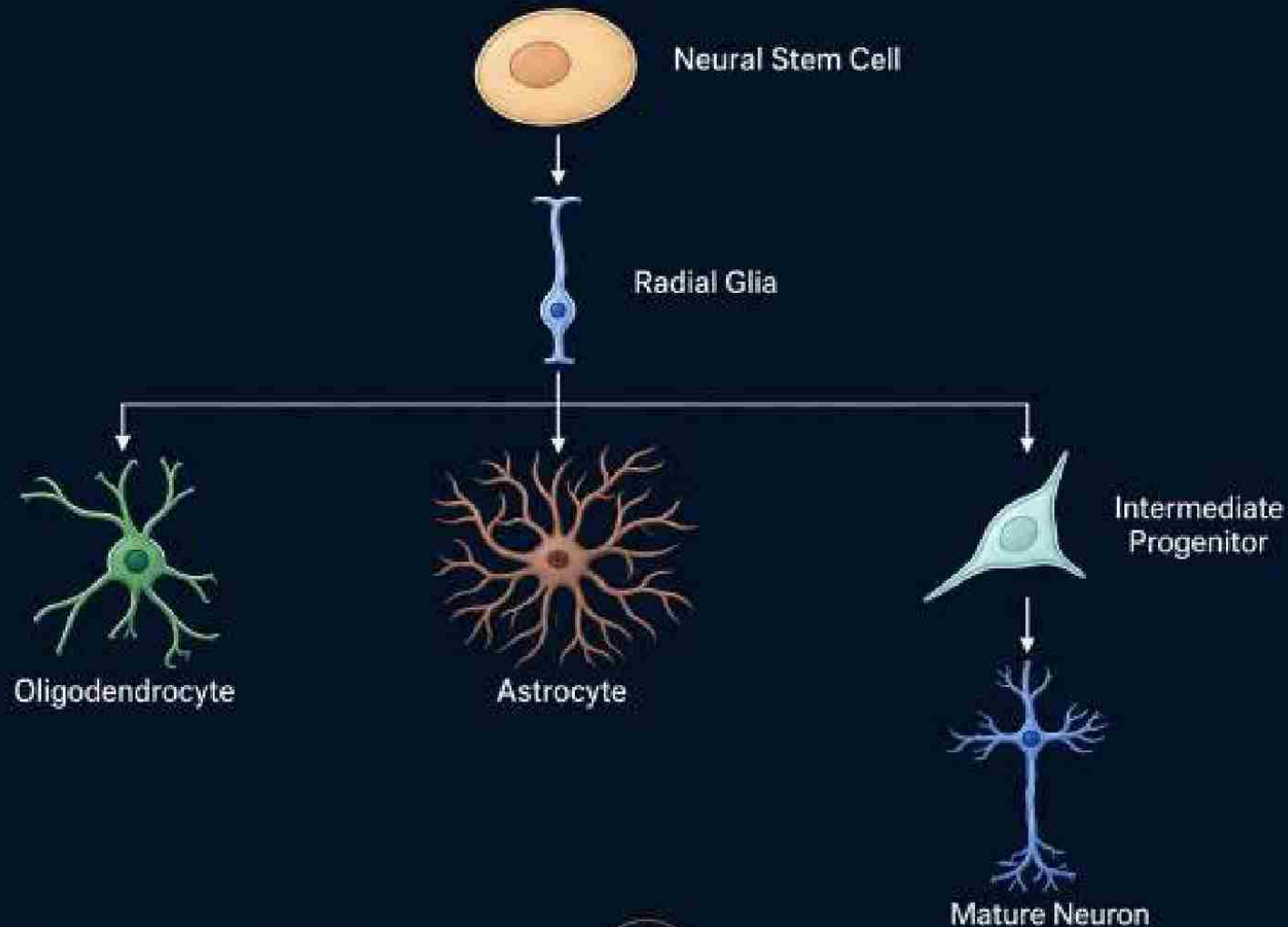
Neurulation

Early neural plate folding and neural tube closure.



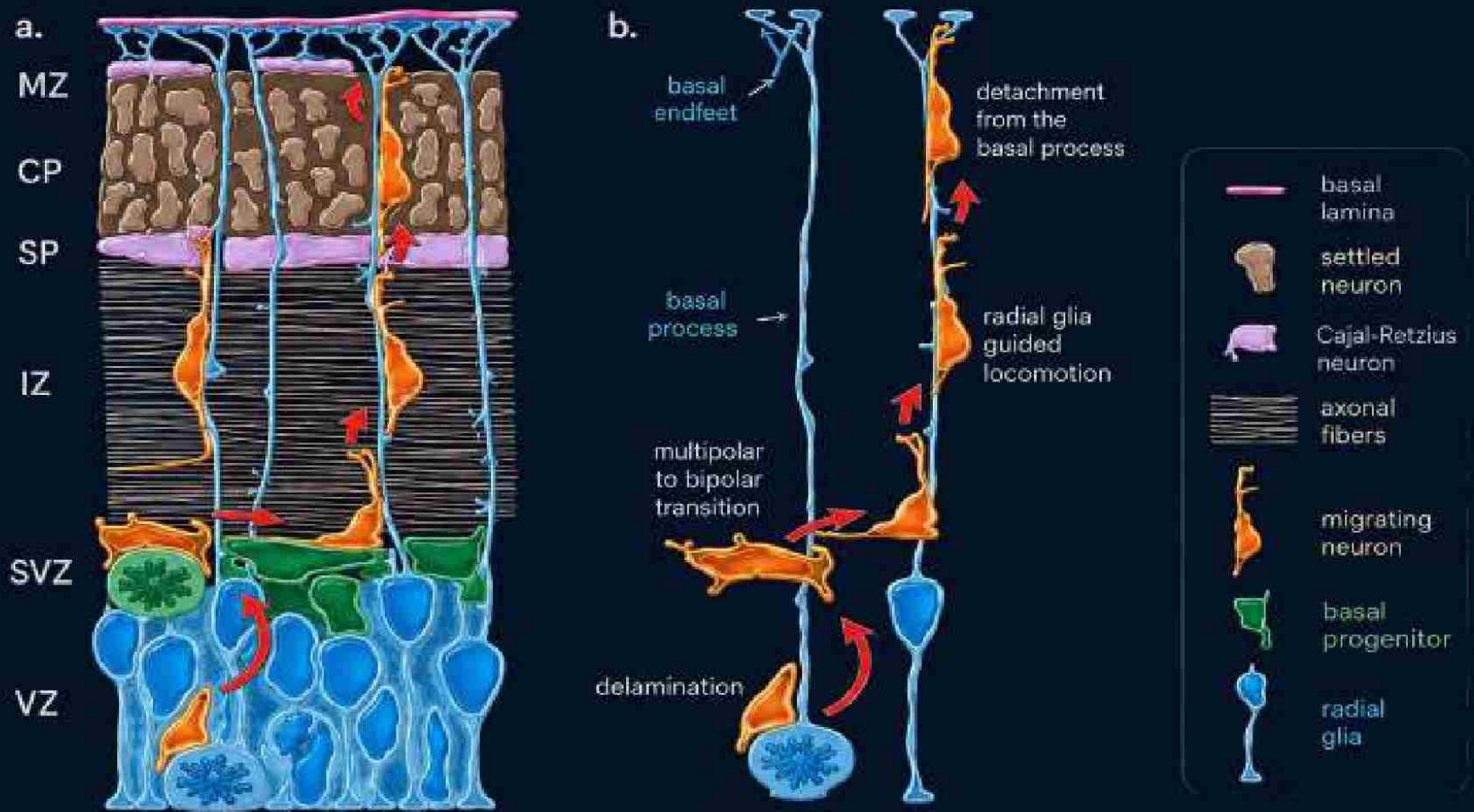
From neural stem cell to cortical neurons

Radial glia give rise to major neural cell lineages in the developing cortex.



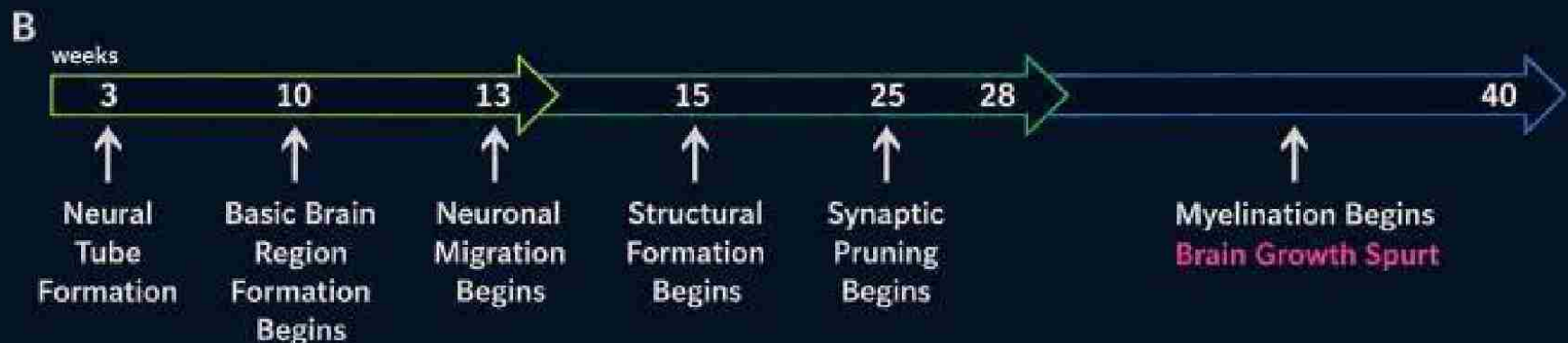
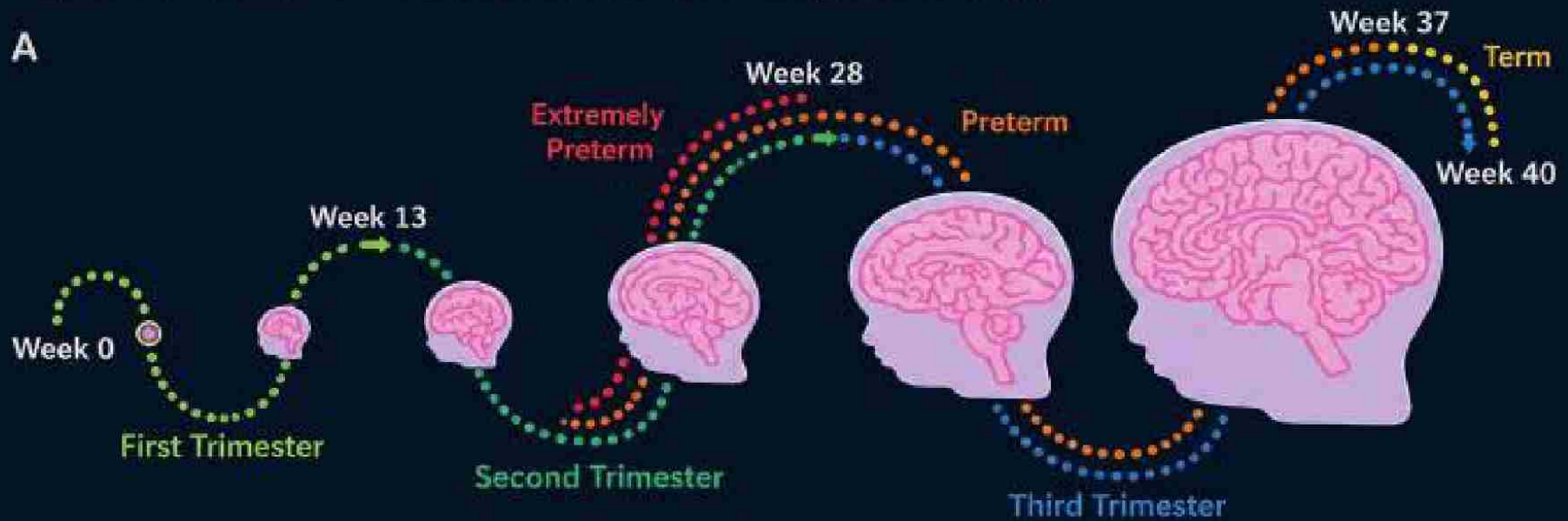
Cortical layers and neuronal migration

Radial glia-guided locomotion through transient cortical zones.



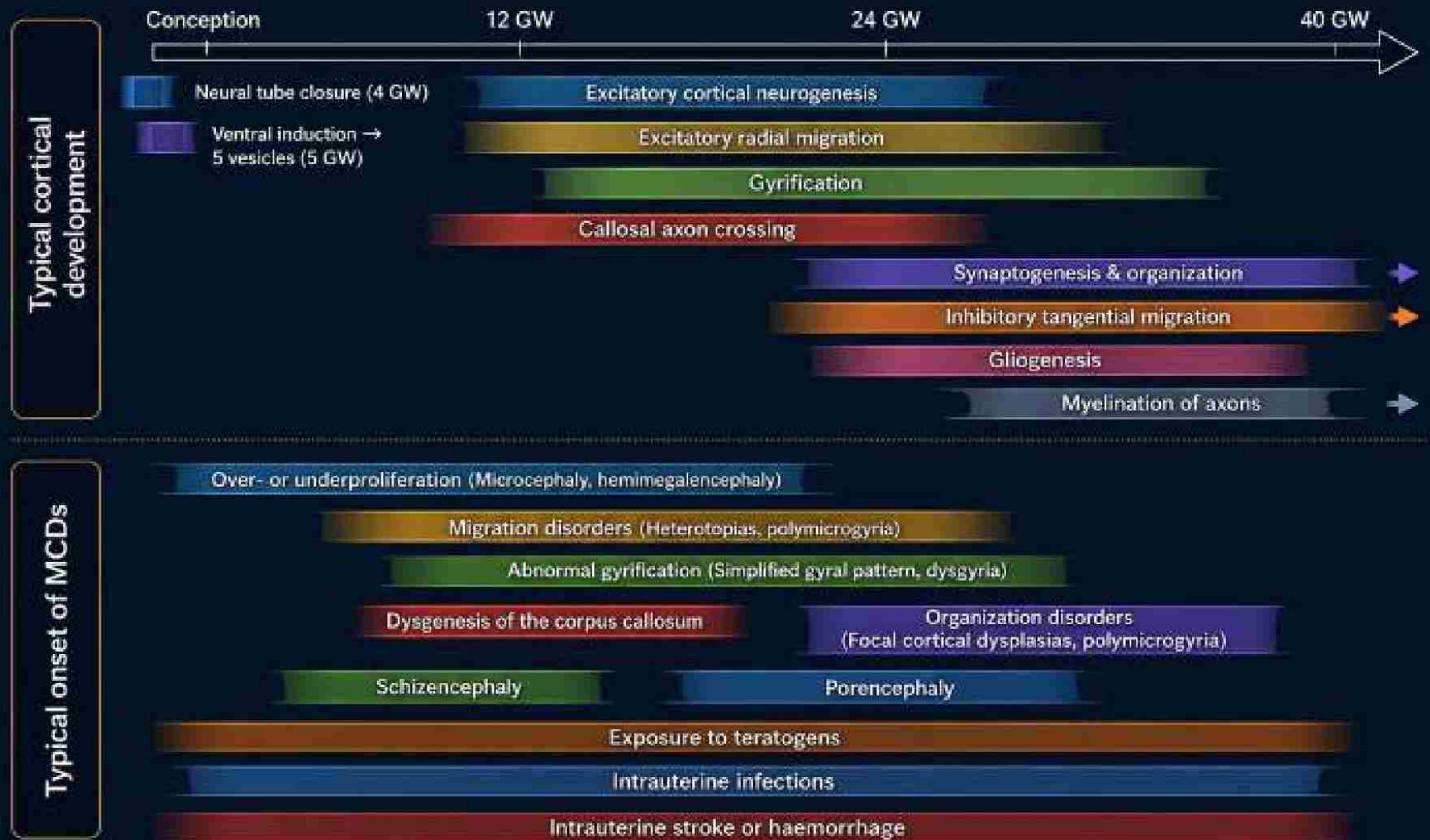
Fetal brain developmental timeline

Major prenatal milestones across trimesters and gestational age.



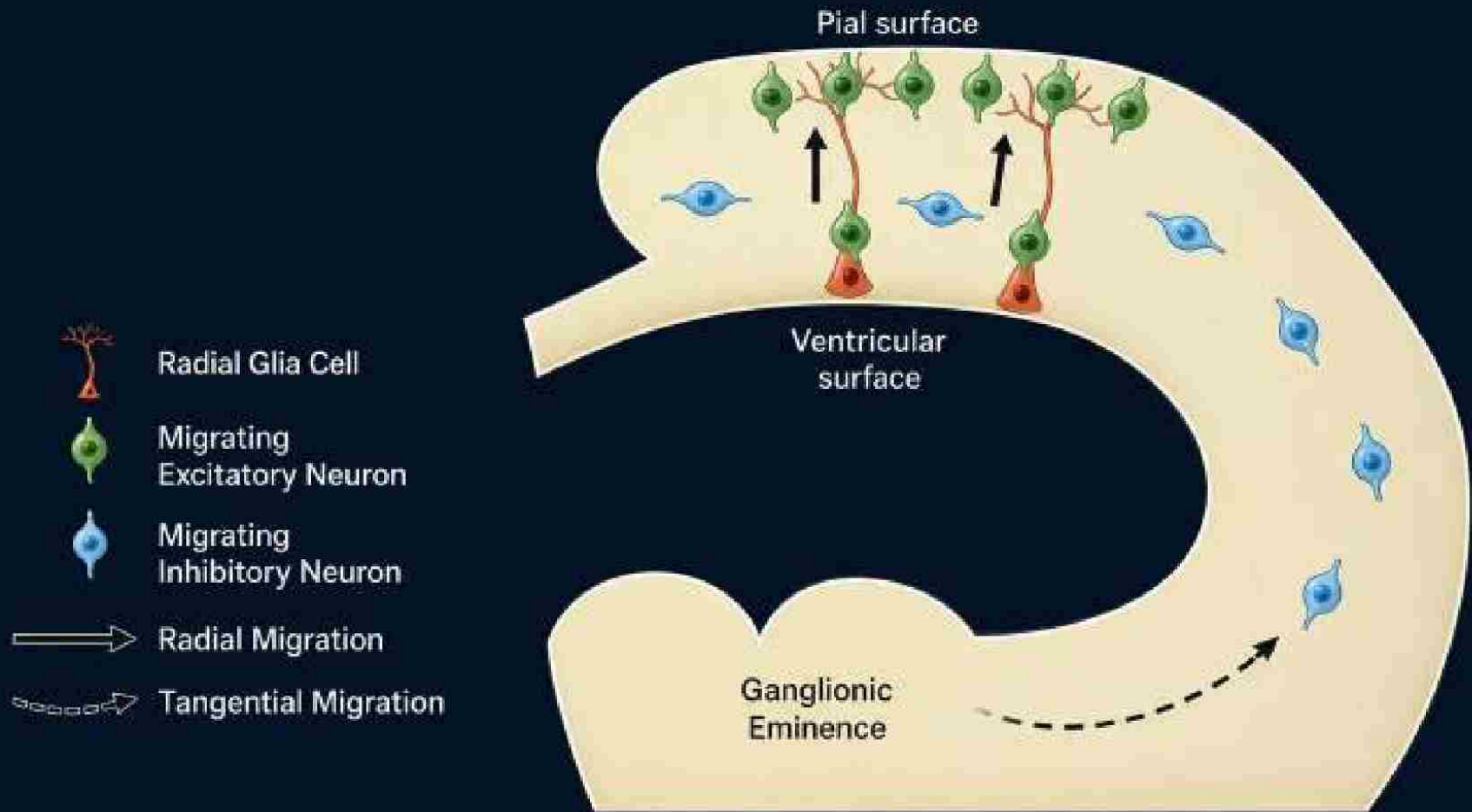
Typical cortical development and onset of MCDs

Developmental windows across gestational weeks and corresponding malformation risk periods.



Radial and tangential neuronal migration

Excitatory neurons migrate radially along radial glia, whereas inhibitory neurons migrate tangentially from the ganglionic eminence.



Sulcation Milestones

Key fetal cortical folding landmarks across gestation.

- 01 • **16–18 weeks:** Sylvian fissure visible
- 02 • **20–22 weeks:** Parieto-occipital fissure
- 03 • **24–26 weeks:** Central sulcus begins
- 04 • **28 weeks:** Secondary sulci appear
- 05 • **32–34 weeks:** Complex gyral pattern
- 06 • **Term:** Mature cortical appearance



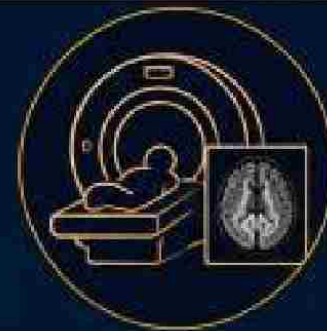Prenatal Imaging

Key roles of ultrasound and fetal MRI in evaluating fetal cortical development.



Ultrasound

- Assessment of sulcation and ventricles
- Detection of major anomalies



Fetal MRI

- Better evaluation of migration and cortical malformations
- Useful in ventriculomegaly and suspected syndromes



Common Cortical Malformations

Key examples of abnormal cortical development and migration disorders.

01

• **Lissencephaly** – smooth brain

02

• **Polymicrogyria** – excessive small gyri

03

• **Schizencephaly** – cerebral clefts

04

• **Gray matter heterotopia** – failed migration


05

• **Focal cortical dysplasia** – abnormal organization



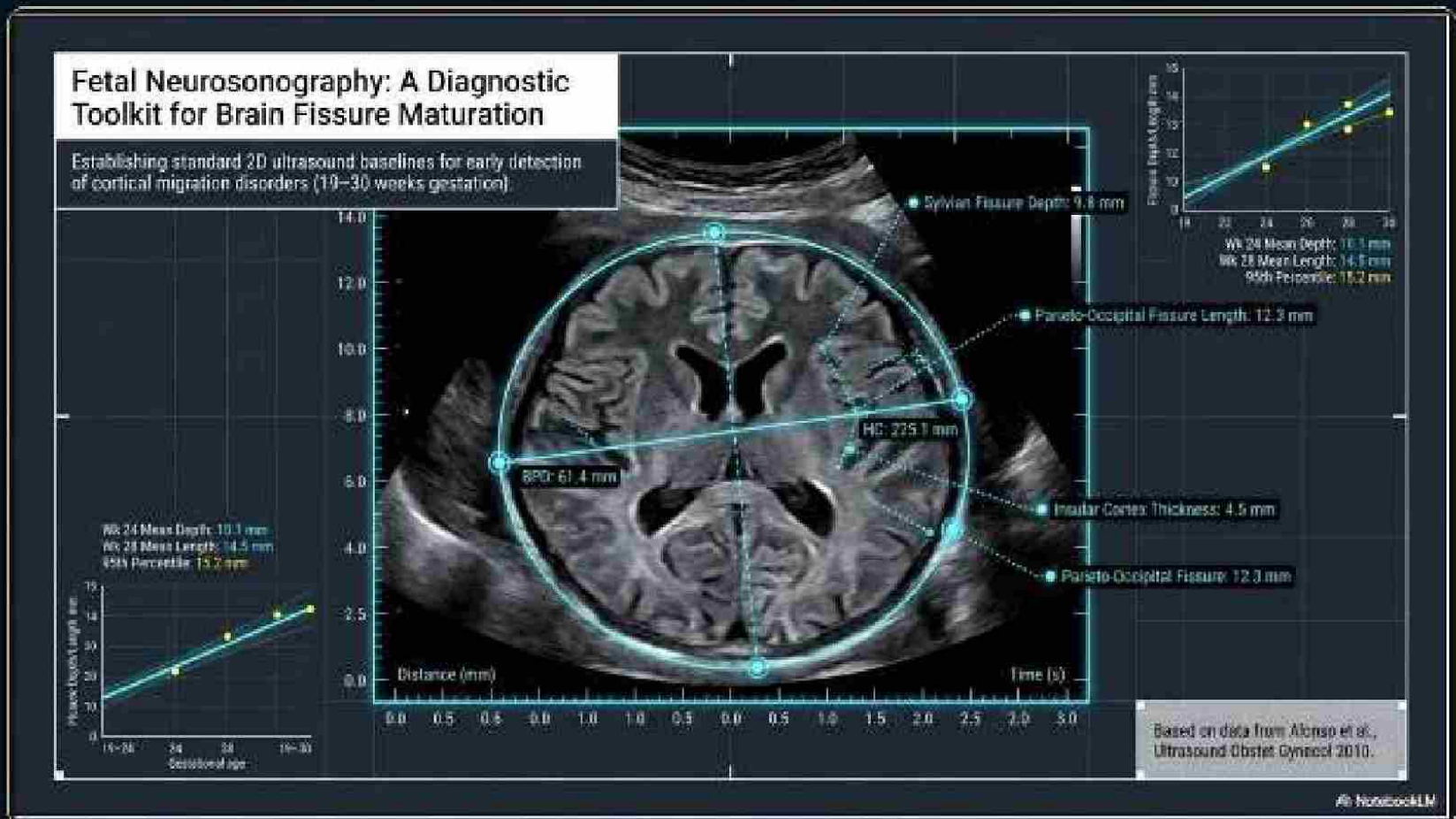
Development Timeline

Timeline of fetal cortical development across gestational weeks.



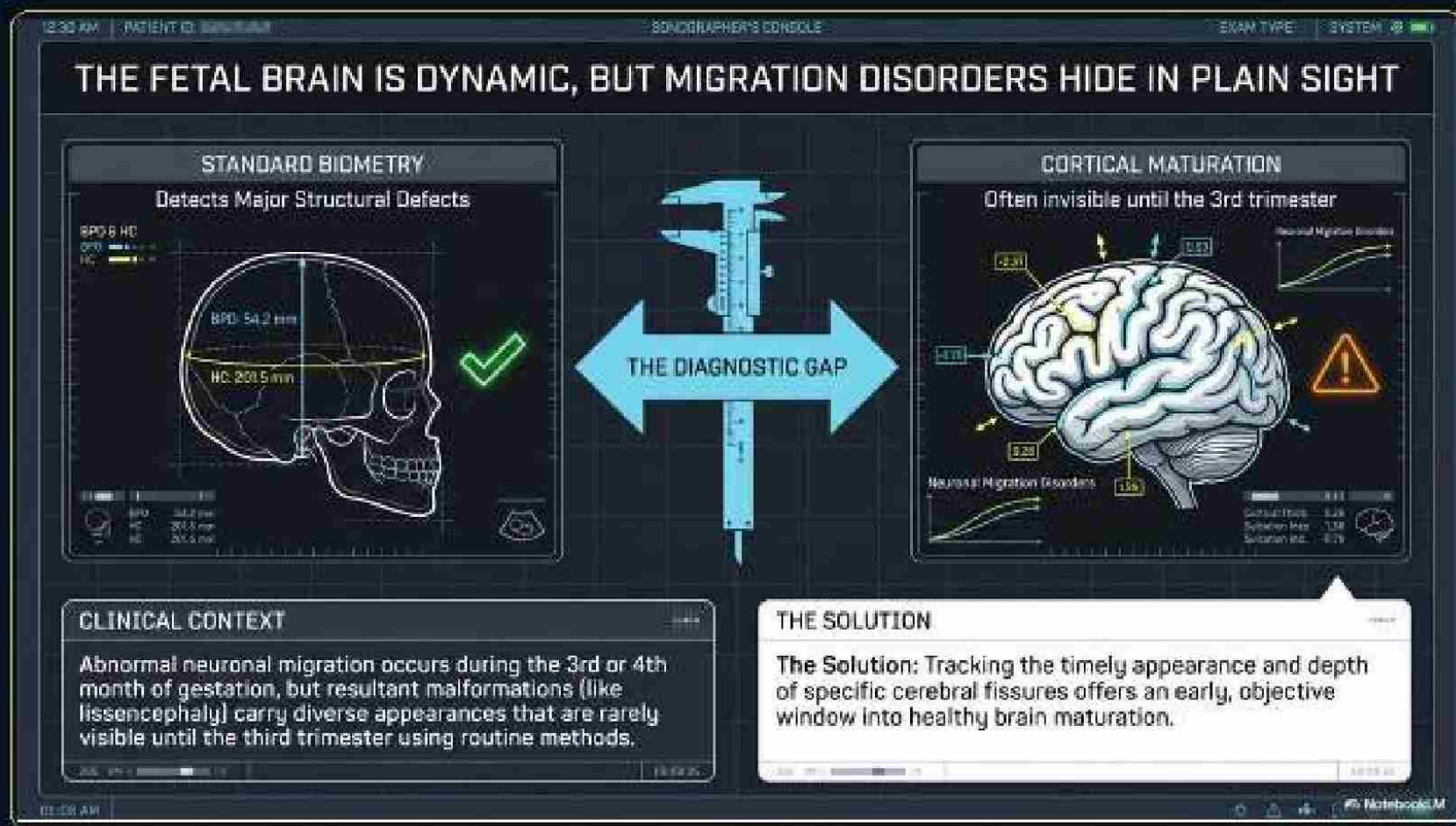
Ultrasound & Neuroimaging Figure 1

Fetal neurosonography: diagnostic toolkit for brain fissure maturation.



Ultrasound & Neuroimaging Figure 2

Diagnostic gap: routine biometry vs cortical maturation assessment.



Ultrasound & Neuroimaging Figure 3

Study parameters dashboard for standardized fissure assessment.

THE EVIDENCE BASE: STANDARDIZING FISSURE ASSESSMENT

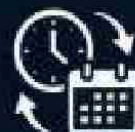Study Parameters Dashboard



SAMPLE POPULATION

180 NORMAL FETUSES

Strict inclusion: Singleton pregnancies, normally grown, no structural defects.



GESTATIONAL TIMELINE

19 TO 30+6 WEEKS

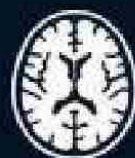Measured prospectively at routine 2nd/3rd trimester scans



IMAGING MODALITY

**2D TRANSABDOMINAL
ULTRASOUND**

No specialized 3D equipment or transvaginal probes required



TARGET STRUCTURES

**4 KEY CEREBRAL
FISSURES**

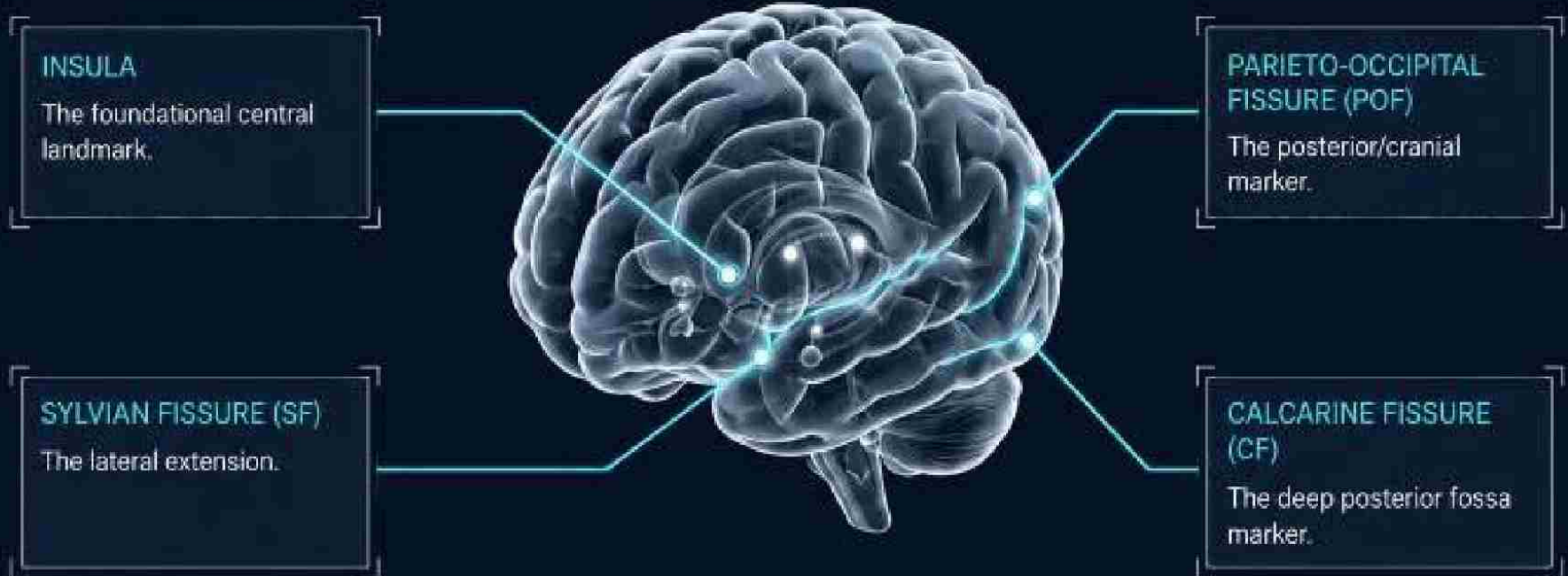
Measured in standard biometric planes

Ultrasound & Neuroimaging Figure 4

Key fissure landmarks used in fetal brain assessment.

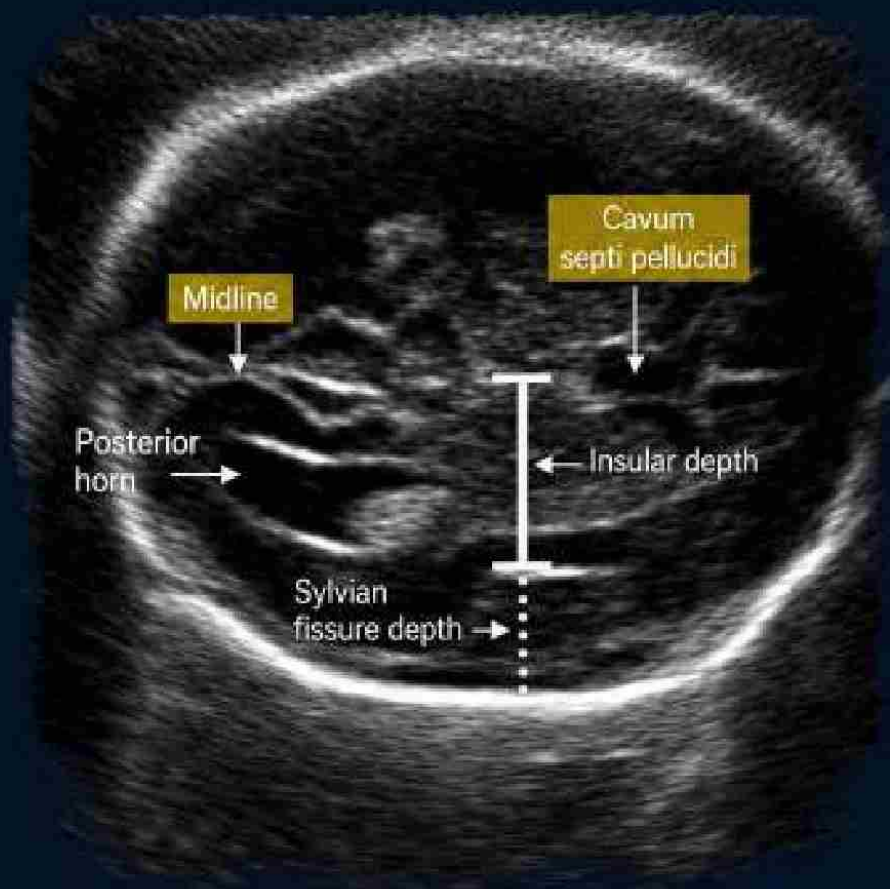
THE FOUR PILLARS OF FETAL BRAIN ASSESSMENT

These four fissures develop at different rates and in distinct anatomical planes. By tracking their depth, sonographers can objectively estimate brain development without altering the routine scan workflow or extending exam time.



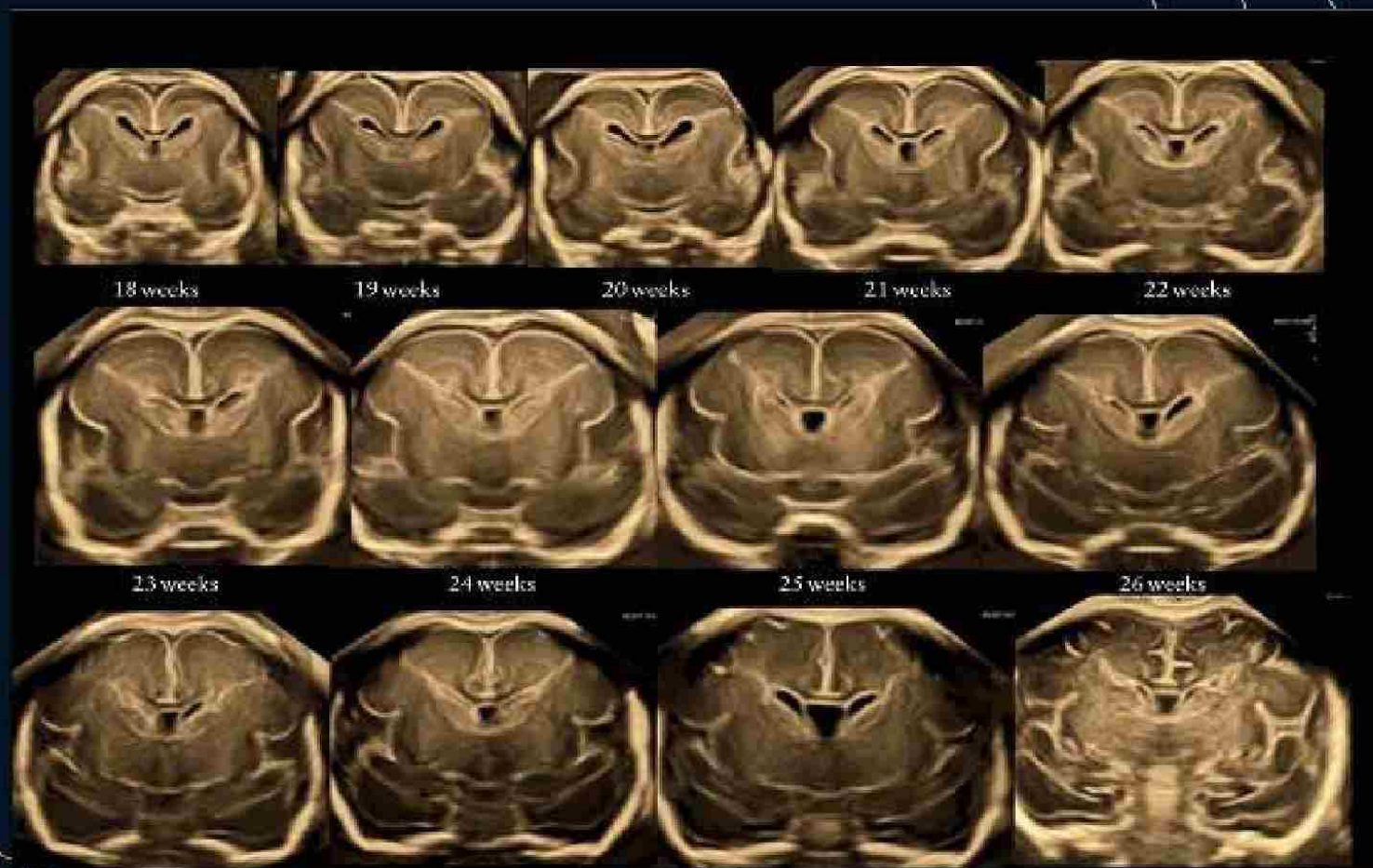
Ultrasound & Neuroimaging Figure 5

PROTOCOL STEP 1: INSULA & SYLVIAN FISSURE (SF)



- 1. Obtain Plane:** Start at the standard transventricular axial plane (used for routine BPD measurement). Ensure the midline is perfectly equidistant from the calvarium.
- 2. Locate Landmarks:** Identify the cavum septi pellucidi, atrium, posterior horns, and choroid plexus.
- 3. Measure Insula:** Draw a perpendicular line from the midline to the upper border of the insular cortex (maximum prominence).
- 4. Measure SF:** Continue that exact line from the insular cortex directly outward to the inner table of the parietal bone.

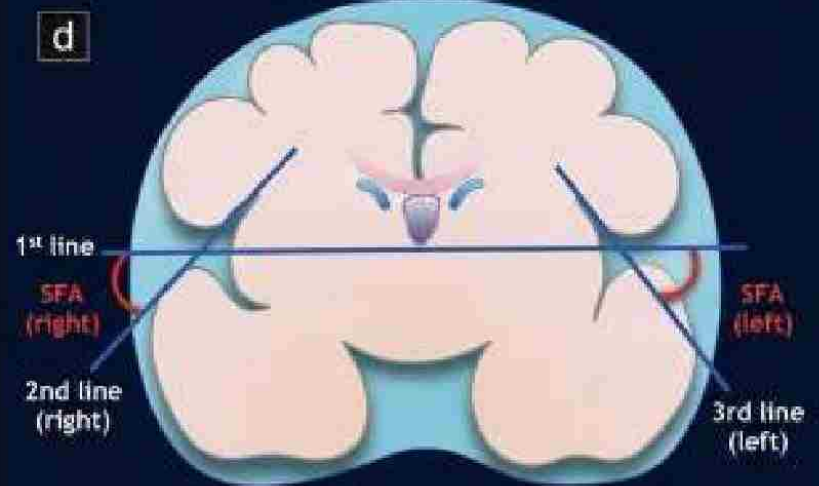
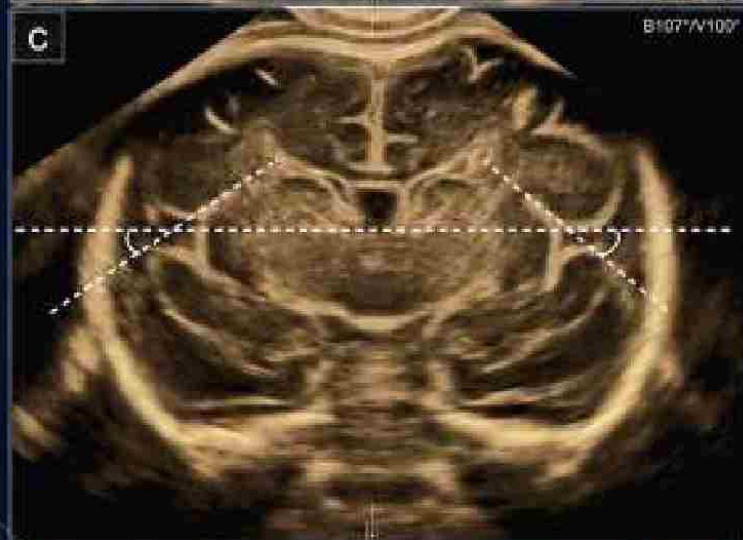
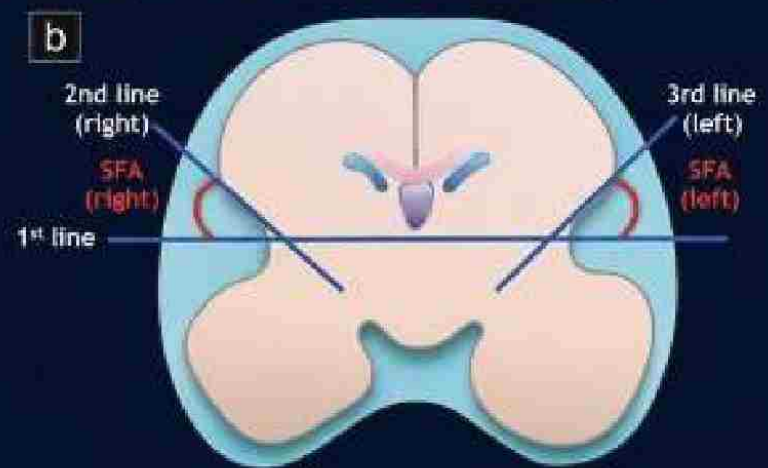
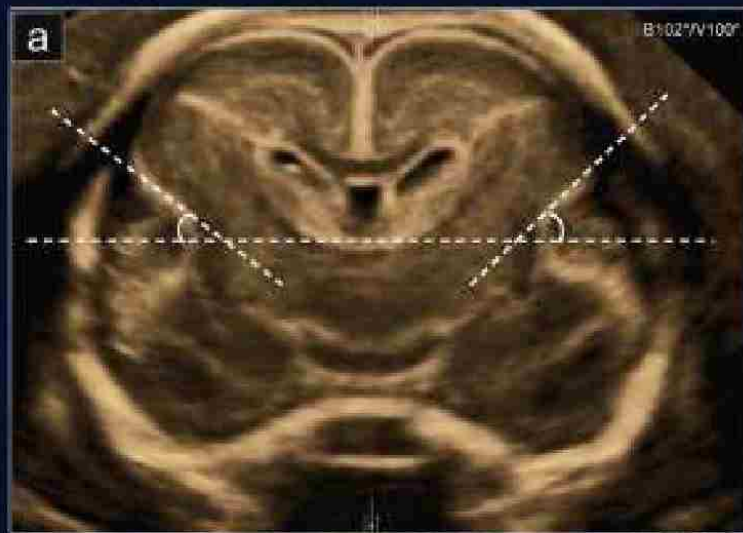
Transvaginal three-dimensional ultrasound assessment of Sylvian fissures at 18-30 weeks' gestation



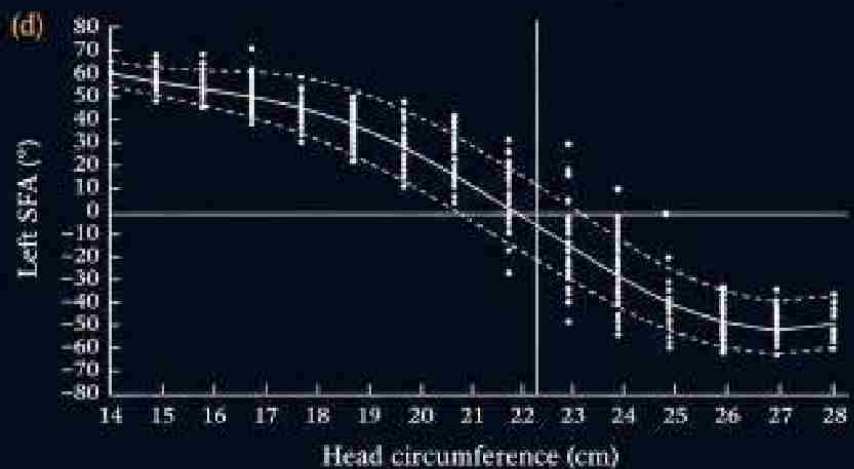
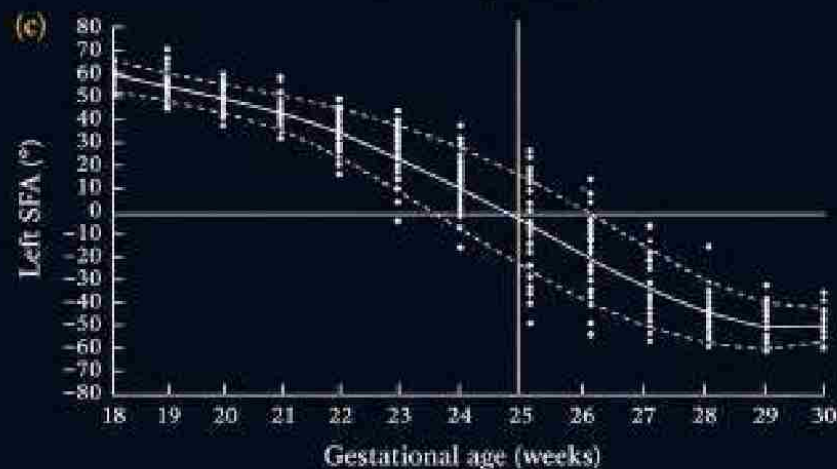
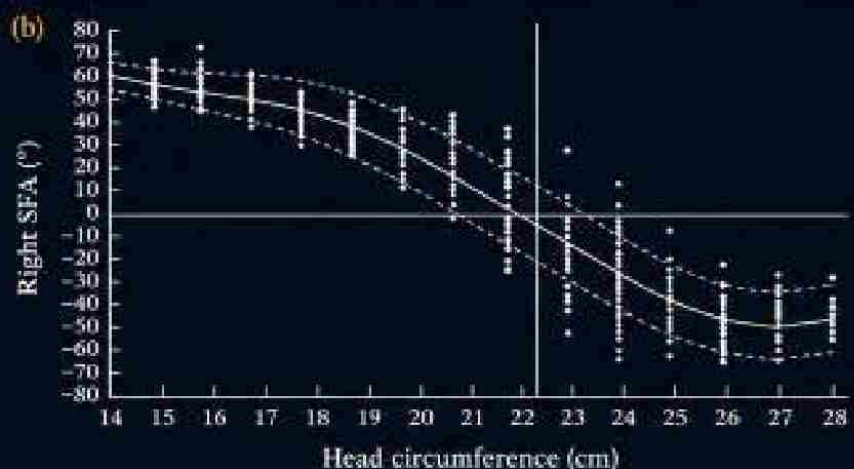
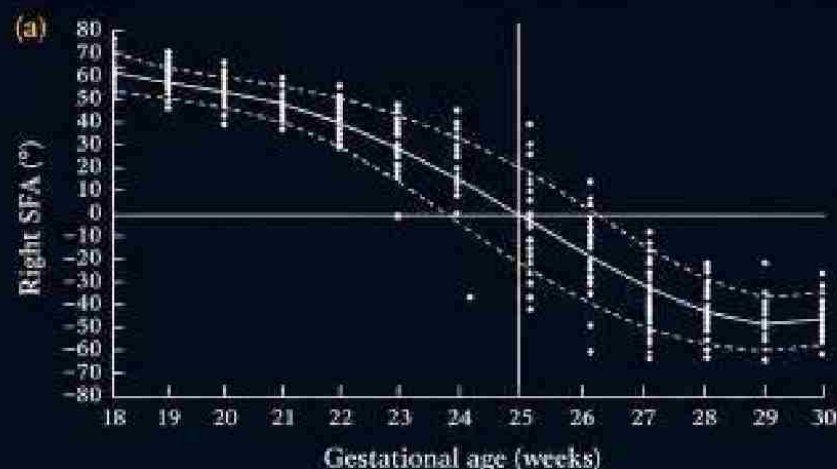
Ultrasound in Obstet & Gyne, Volume: 54, Issue: 2, Pages: 190-198, First published: 31 October 2018, DOI: (10.1002/uog.20172)



Transvaginal three-dimensional ultrasound assessment of Sylvian fissures at 18–30 weeks' gestation

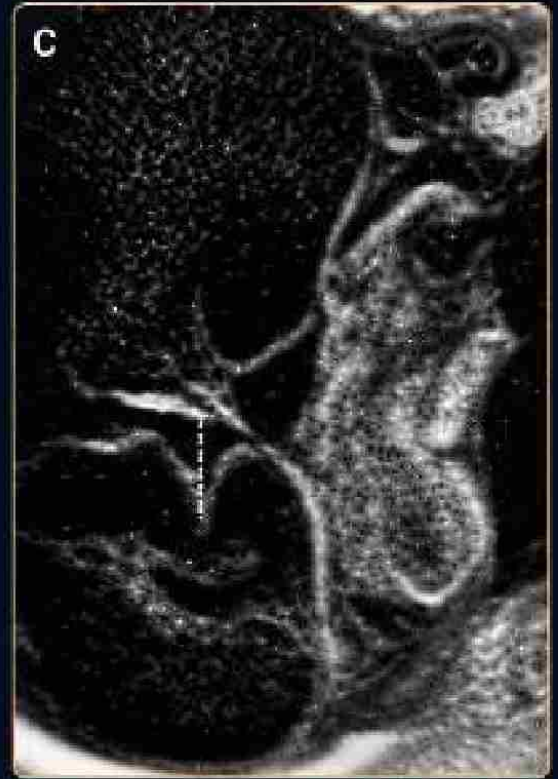
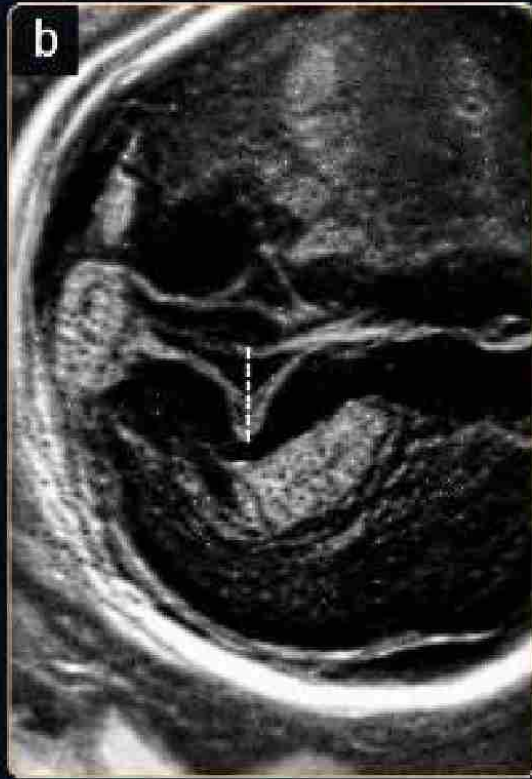
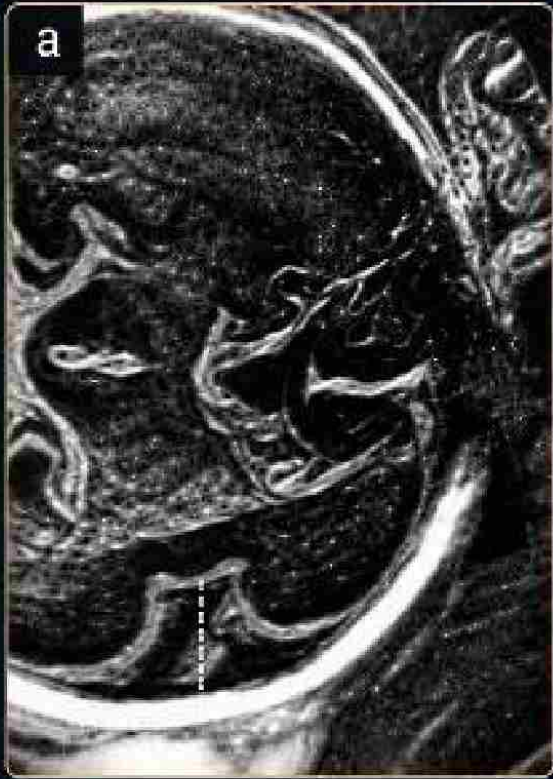TRANSVAGINAL THREE-DIMENSIONAL ULTRASOUND ASSESSMENT OF SYLVIAN FISSURES AT 18-30 WEEKS' GESTATION

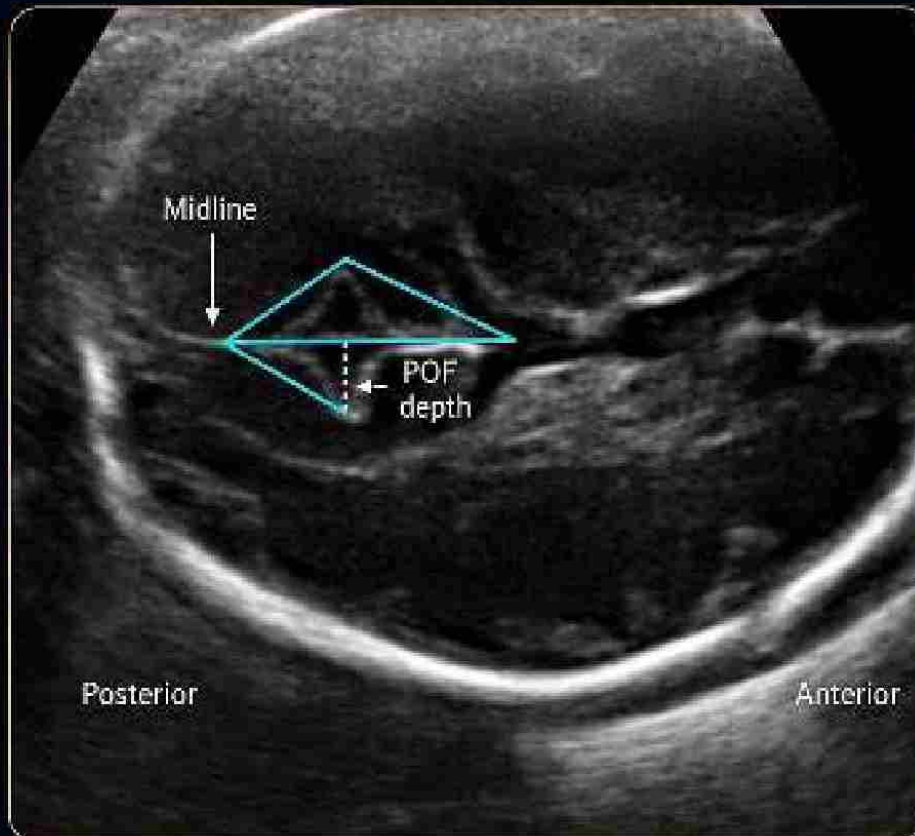


Ultrasound in Obstet & Gyne, Volume: 54, Issue: 2, Pages: 190-198, First published: 31 October 2018, DOI: (10.1002/uog.20172)





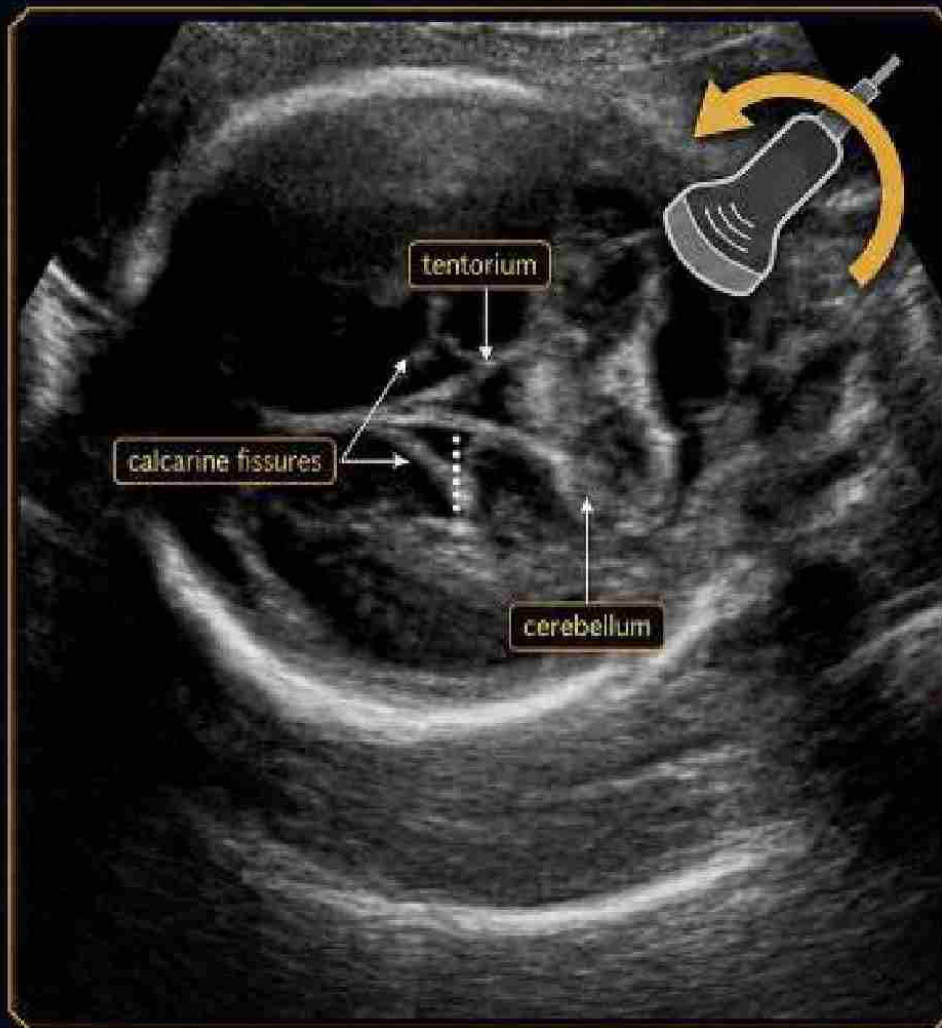
PROTOCOL STEP 2: PARIETO-OCCIPITAL FISSURE (POF)



- 1. Obtain Plane:**
Start at the standard BPD axial plane.
- 2. Adjust Probe:**
Move the probe cranially, keeping it parallel to the BPD plane, until the full depth of the fissure appears.
- 3. Identify Shape:**
Look for the characteristic triangular shape, with the apex pointing away from the brain's midline.
- 4. Measure POF:**
Draw a line strictly perpendicular from the midline, extending precisely to the apex of the fissure.



PROTOCOL STEP 3: CALCARINE FISSURE (CF)



1. Obtain Plane: Start at the axial transcerebellar plane (used for transcerebellar diameter).

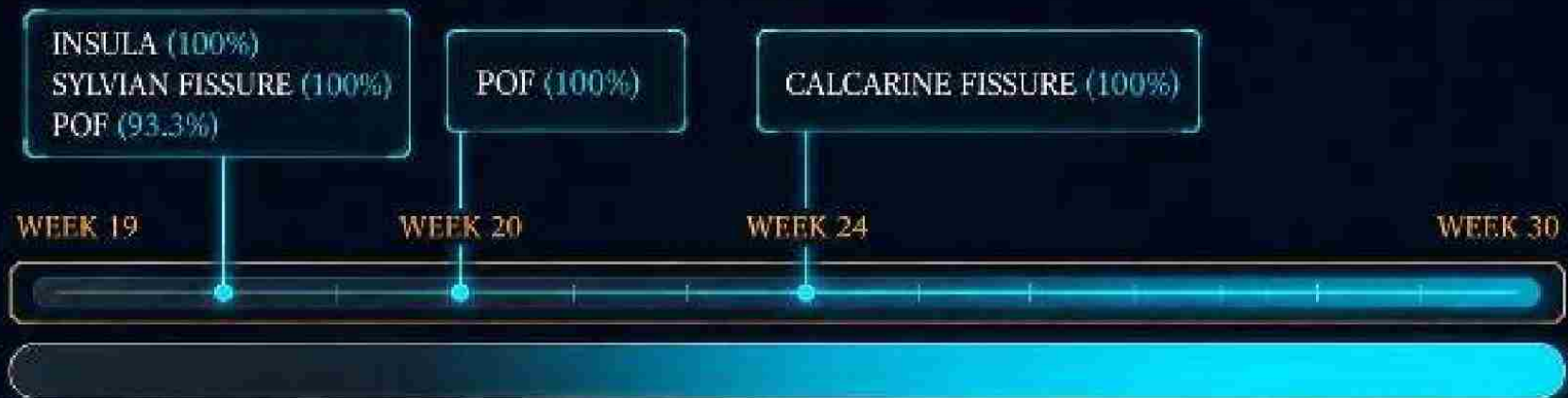2. Adjust Probe (The 90° Maneuver): Turn the probe exactly 90 degrees to obtain a coronal view of the posterior fossa.

3. Locate Landmarks: Ensure the CF is completely visualized above the cerebellum.

4. Measure CF: Draw a line perpendicular to the tentorium (or perpendicular to an imaginary line between the central portions of adjacent gyri).



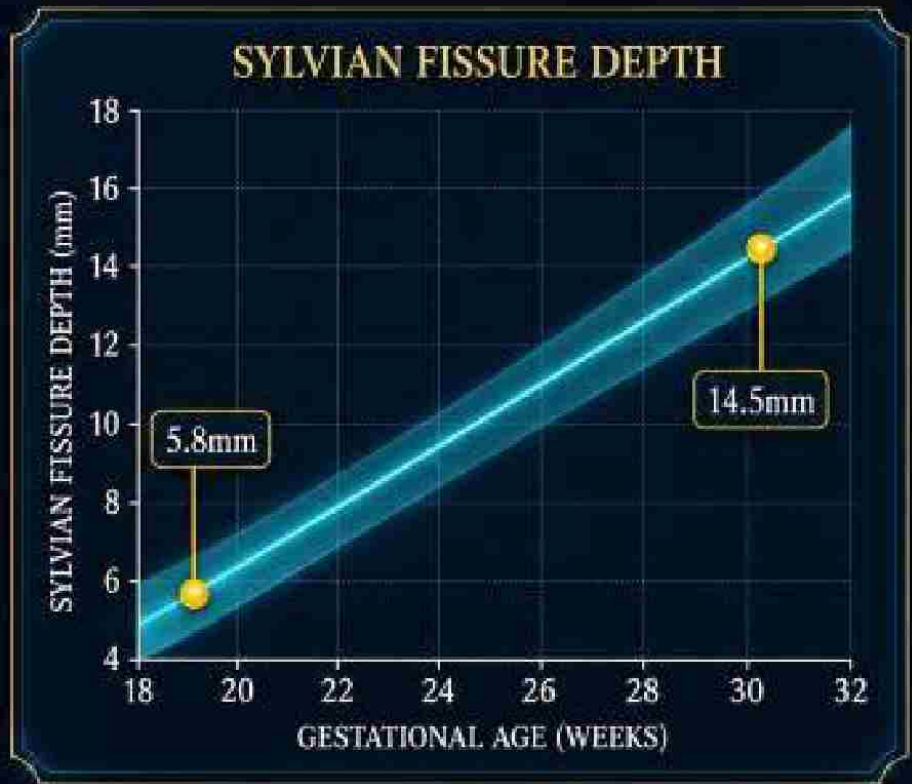
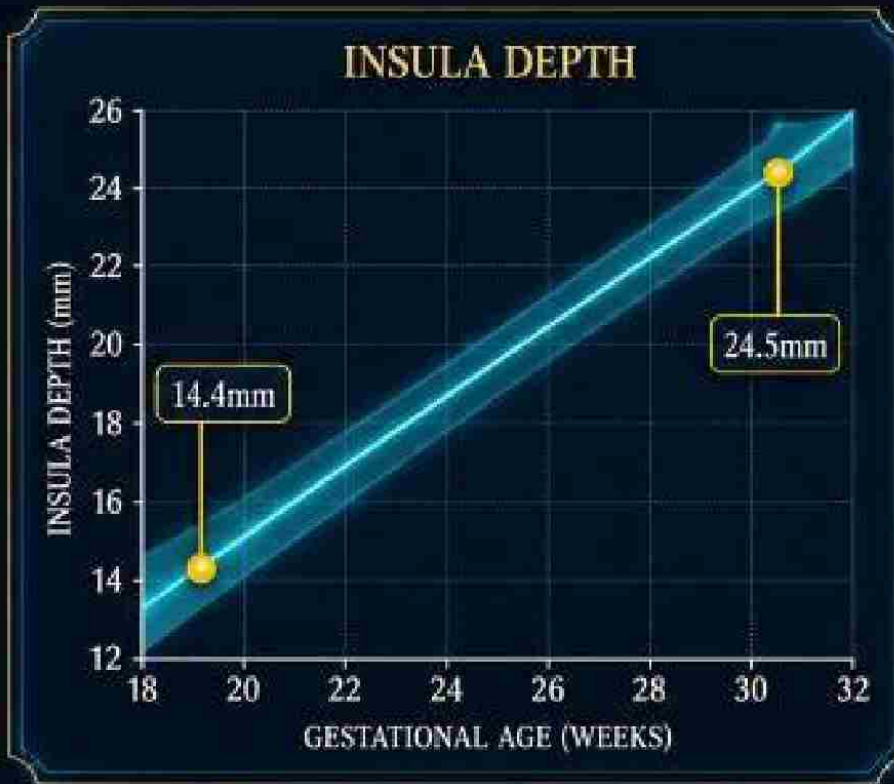
THE DEVELOPMENTAL TIMELINE: WHEN TO EXPECT VISIBILITY



Transabdominal visualization is heavily dependent on gestational age. Failure to visualize the CF at week 20 is normal (only 73.3% visible), whereas failure to see the Insula at week 19 is a clinical red flag. By week 24, all four structures must be 100% visible in a healthy fetus.



Maturation trajectories: Insula & Sylvian fissure

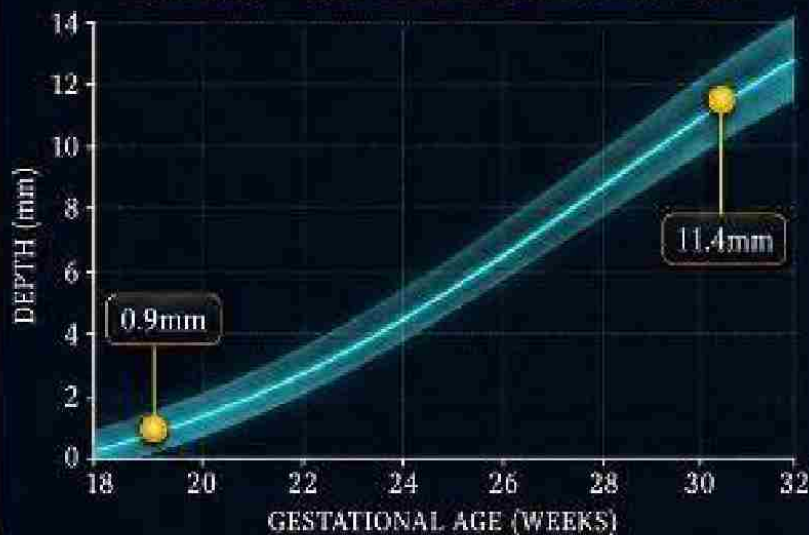


Both structures exhibit highly predictable, statistically significant linear growth ($r = 0.965$ and $r = 0.911$, respectively; $P < 0.0001$). Depth increases reliably by roughly $\sim 1\text{mm}$ per week of gestation. Deviations from these narrow percentile bands serve as early indicators of altered development.

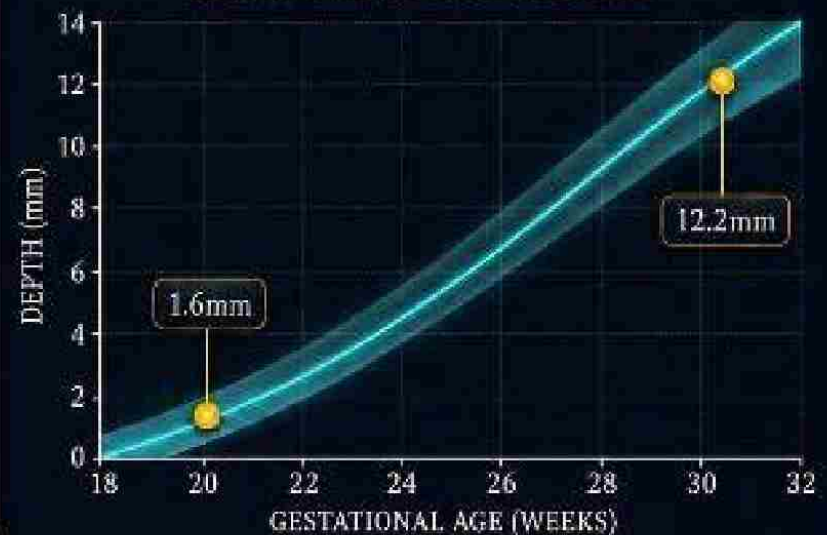

MATURATION TRAJECTORIES: PARIETO-OCCIPITAL & CALCARINE FISSURES

PARIETO-OCCIPITAL FISSURE DEPTH



CALCARINE FISSURE DEPTH



These posterior/cranial fissures begin visibly shallower but experience explosive, linear growth through the late second and early third trimesters ($P < 0.0001$). Because these fissures are virtually non-existent at 19 weeks and grow to over 11 mm by week 30, their rapid expansion offers a highly sensitive timeline for tracking normal brain maturation.



DIAGNOSTIC RELIABILITY: CAN WE TRUST THE MEASUREMENTS?

Reproducibility analysis proves robust agreement. Standard 2D ultrasound calipers consistently yield narrow 95% Confidence Intervals regardless of whether measurements are repeated by the same operator or a secondary clinician.

	INTRAOBSERVER (SAME OPERATOR)	INTEROBSERVER (DIFFERENT OPERATORS)
INSULA	✓	✓
SYLVIAN FISSURE (SF)	✓	✓
PARIETO-OCCIPITAL FISSURE (POF)	✓	✓
CALCARINE FISSURE (CF)	✓	✓



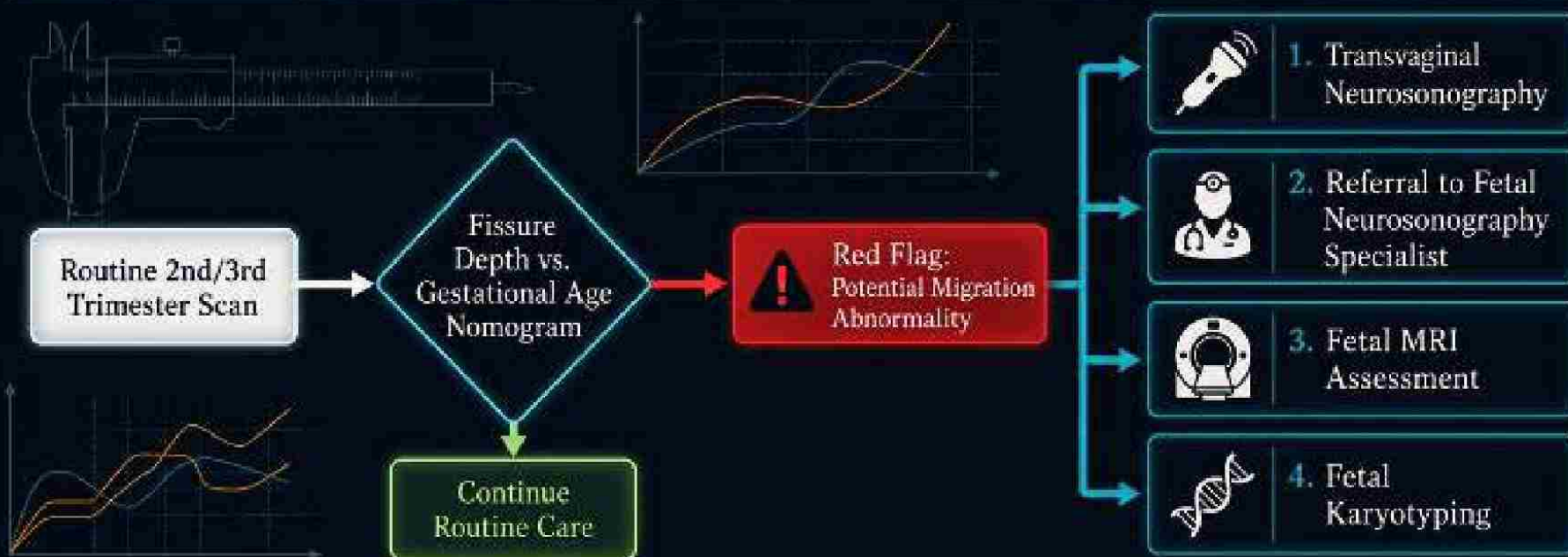
NOTE ON FETAL GENDER

While males statistically show marginally larger Sylvian and Parieto-Occipital fissures, the difference (mean delta <math><0.6\text{mm}</math>) is clinically irrelevant for standard screening purposes.








CLINICAL APPLICATION: FROM MEASUREMENT TO MANAGEMENT

Fissure depth acts as an early warning system. Mild or localized forms of lissencephaly may lack other obvious markers. Abnormal fissure development must trigger immediate second-line diagnostic assessments to ensure proper counseling and management.





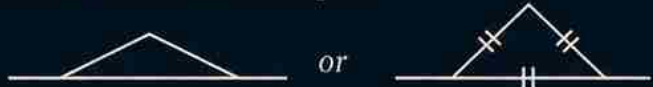









THE SONOGRAPHER'S QUICK-REFERENCE MATRIX

FISSURE 	DIAGNOSTIC PLANE 	PROBE MANEUVER 	KEY ANATOMICAL LANDMARKS 	100% VISIBILITY TARGET 	GROWTH RANGE (19W-30W) 
Insula	Transventricular Axial	Standard BPD	Cavum septi pellucidi, Midline	Week 19	14.4mm → 24.5mm
SF	Transventricular Axial	Standard BPD	Insular cortex, Parietal bone	Week 19	5.8mm → 14.5mm
POF	Parallel Cranial Axial	Move cranial from BPD	Triangular shape apex	Week 20	0.9mm → 11.4mm
CF	Coronal Posterior Fossa	90° Turn from Cerebellar	Tentorium, Cerebellum	Week 24	1.6mm (20w) → 12.2mm



Grade and symmetry of normal fetal cortical development: a longitudinal two- and three-dimensional ultrasound study

Grade	Definition & diagram	Example
0	None visible 	
1	Earliest changes (shallow indentation or echogenic dot) 	
2	Broad V (width \geq depth) 	
3	Y or narrow V (depth $>$ width) 	
4	I- or J-shaped 	
5	Branched 	















Grade and symmetry of normal fetal cortical development: a longitudinal two- and three-dimensional ultrasound study

Grade	Definition & diagram	Example
1	Shallow indentation 	
2	Obtuse angular shape 	
3	Acute angles, < 50% operculization 	
4	$\geq 50\%$ operculization 	
5	Complete operculization 	

Ultrasound in Obstet & Gyne, Volume: 36, Issue: 6, Pages: 700-708, First published: 24 November 2010, DOI: (10.1002/uog.7705)

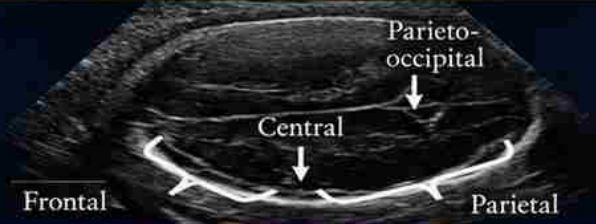
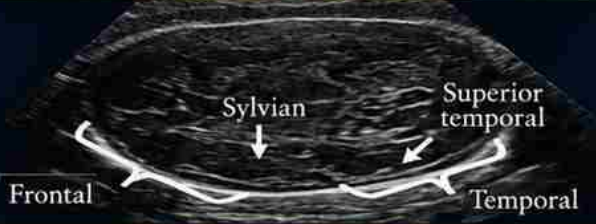





Grade and symmetry of normal fetal cortical development: a longitudinal two- and three-dimensional ultrasound study

Grade	Definition & diagram	Example
0	None visible 	
1	Shallow undulation 	
2	Gyral width > depth 	
3	Gyral width = depth 	
4	Gyral depth > width 	
5	Branched gyri-/ sulci 	

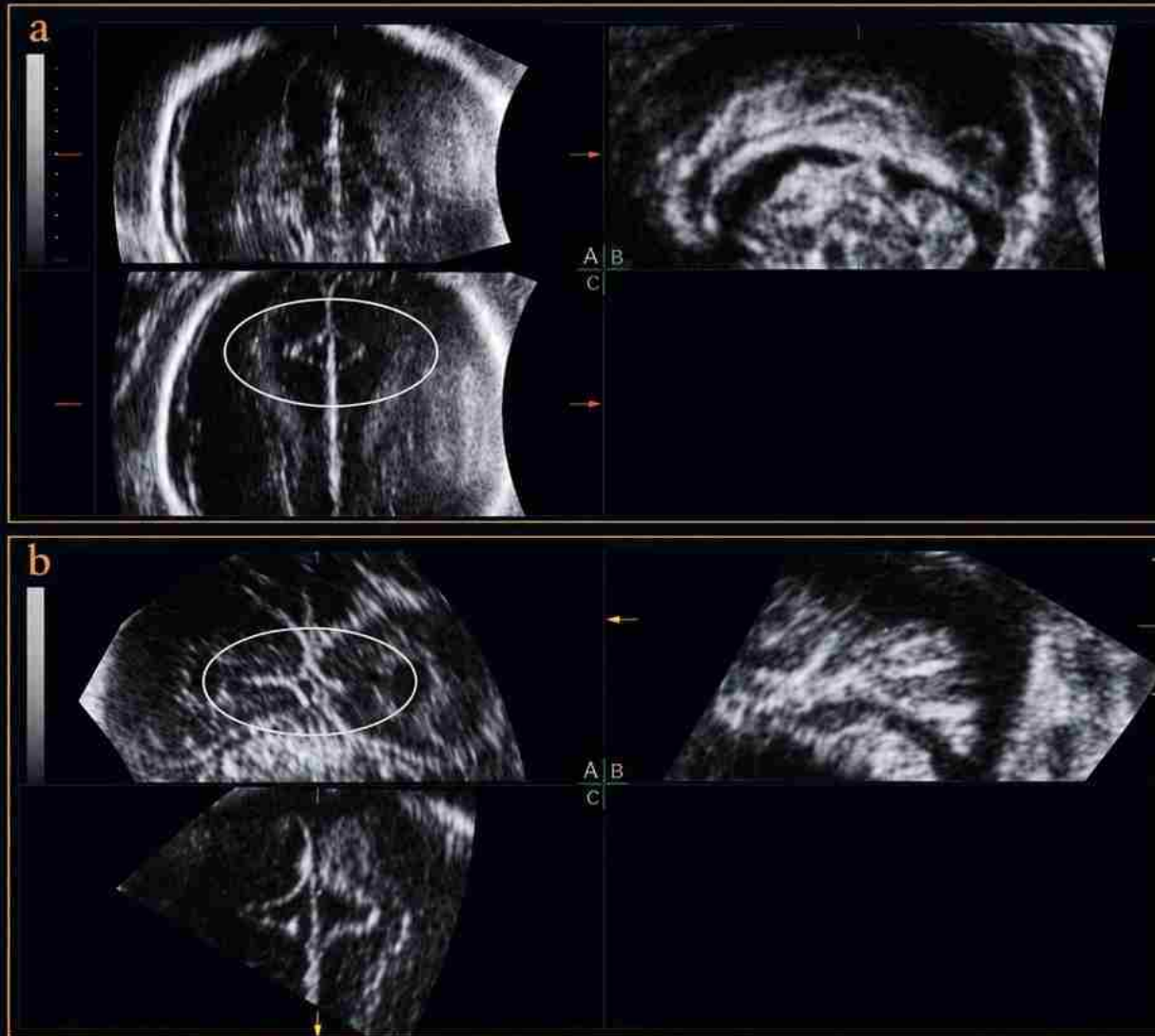


Grade and symmetry of normal fetal cortical development: a longitudinal two- and three-dimensional ultrasound study

Plane, description, evaluation	Image
1) Axial plane cephalad to the transventricular plane Parieto-occipital fissure Central sulcus Frontal area Parietal area	 <p>This axial ultrasound image shows a cross-section of the fetal brain. Labels include 'Parieto-occipital' with a downward arrow pointing to a deep fissure, 'Central' with a downward arrow pointing to a shallower sulcus, 'Frontal' on the left side, and 'Parietal' on the right side. White brackets outline the frontal and parietal cortical areas.</p>
2) Axial transthalamic plane Sylvian fissure Superior temporal fissure Frontal area Temporal area	 <p>This axial ultrasound image shows a cross-section of the fetal brain. Labels include 'Sylvian' with a downward arrow pointing to a deep fissure, 'Superior temporal' with a downward arrow pointing to a shallower fissure, 'Frontal' on the left side, and 'Temporal' on the right side. White brackets outline the frontal and temporal cortical areas.</p>
3) Coronal transcaudate and transthalamic plane Cingulate sulcus Mesial area	 <p>This coronal ultrasound image shows a cross-section of the fetal brain. Labels include 'Mesial' on the left and 'Cingulate' on the right, with a bracket and arrow pointing to the cingulate sulcus.</p>
4) Coronal transcerebellar plane Calcarine sulcus Occipital area	 <p>This coronal ultrasound image shows a cross-section of the fetal brain. Labels include 'Calcarine' with a downward arrow pointing to a sulcus, and 'Occipital' on the right side with a bracket indicating the occipital area.</p>
5) Parasagittal oblique plane Central sulcus Frontal area Parietal area	 <p>This parasagittal oblique ultrasound image shows a cross-section of the fetal brain. Labels include 'Frontal' on the left, 'Central' in the middle with a downward arrow pointing to the central sulcus, and 'Parietal' on the right. White brackets outline the frontal and parietal cortical areas.</p>



Grade and symmetry of normal fetal cortical development: a longitudinal two- and three-dimensional ultrasound study

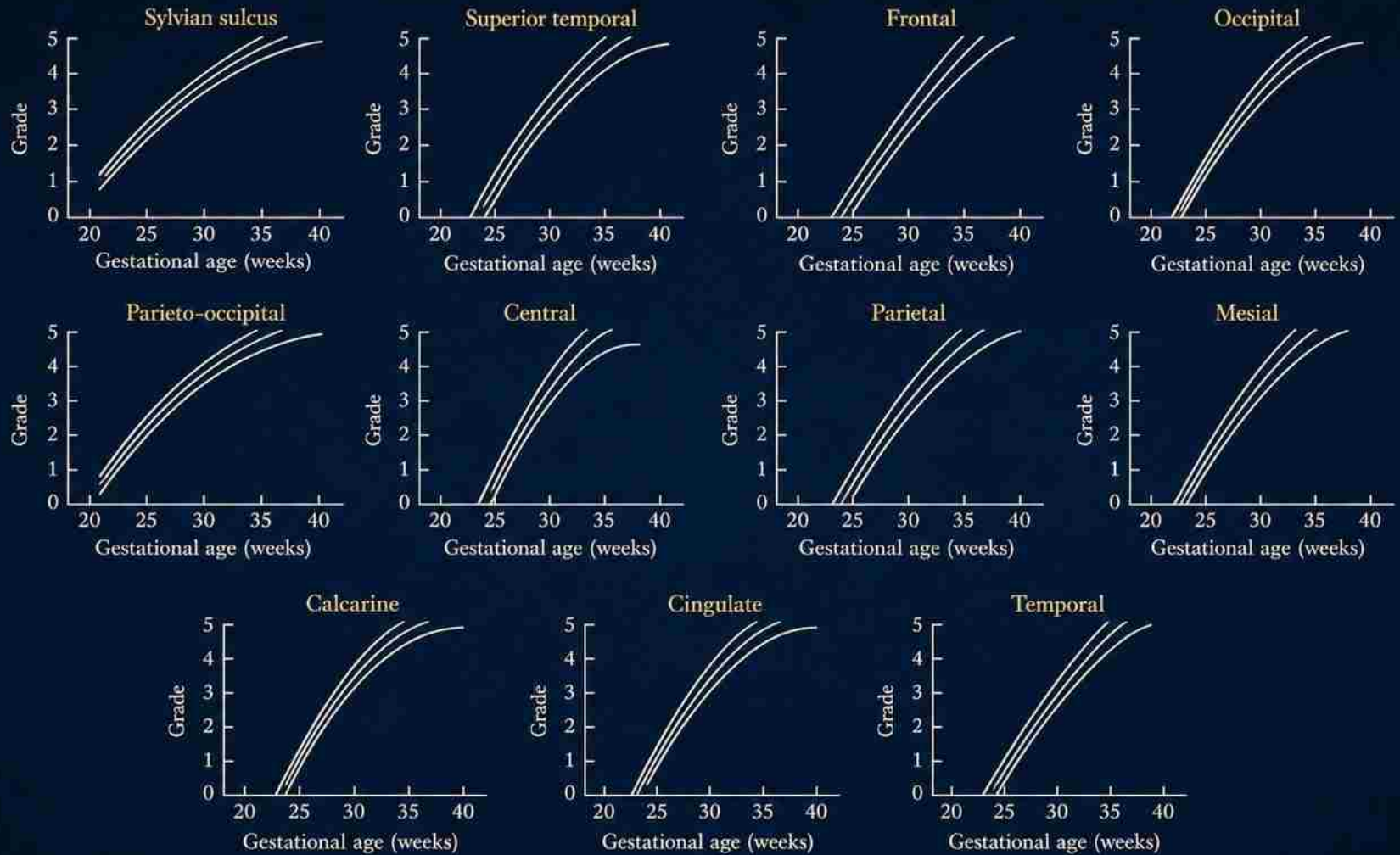


Ultrasound in Obstet & Gyne, Volume: 36, Issue: 6, Pages: 700-708, First published: 24 November 2010, DOI: (10.1002/uog.7705)



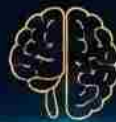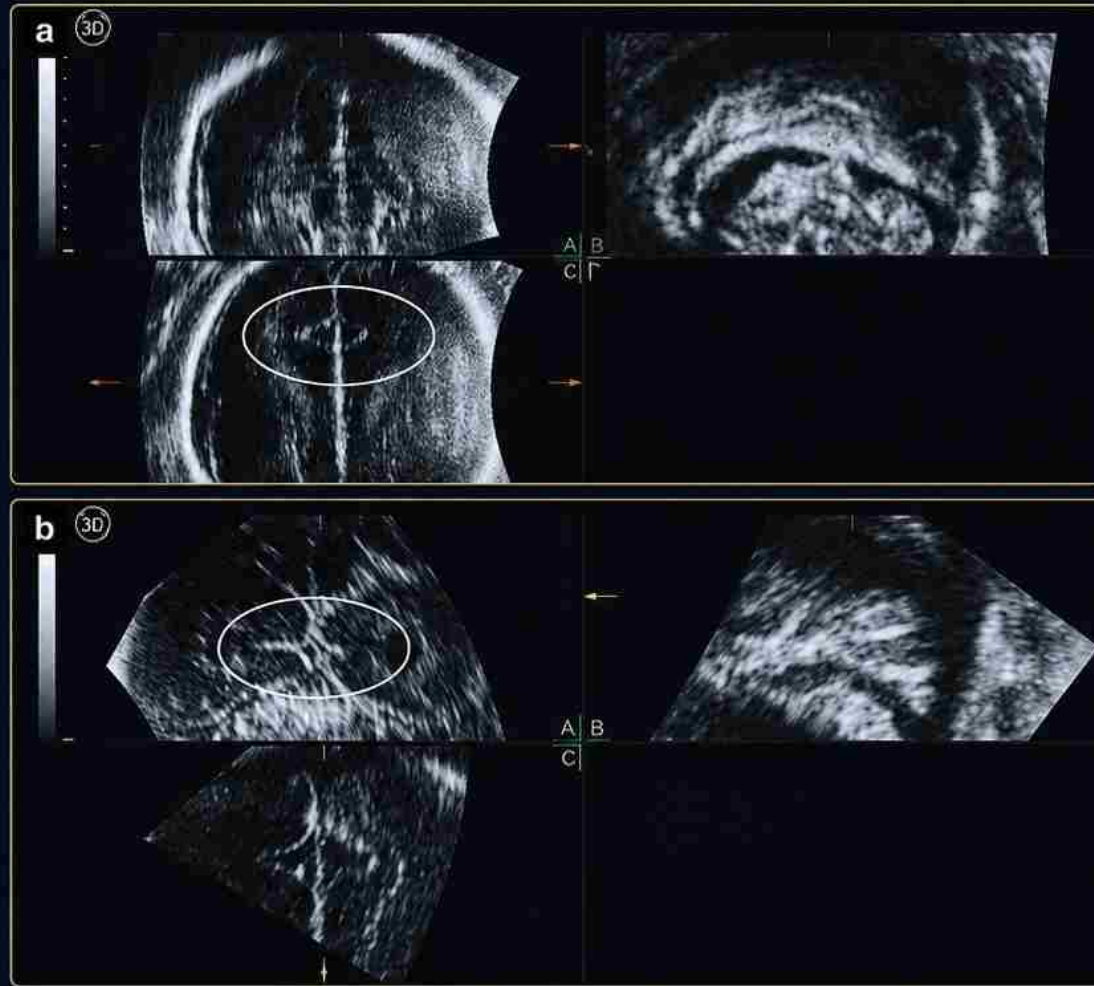
Grade and symmetry of normal fetal cortical development

— Longitudinal 2D and 3D ultrasound study —

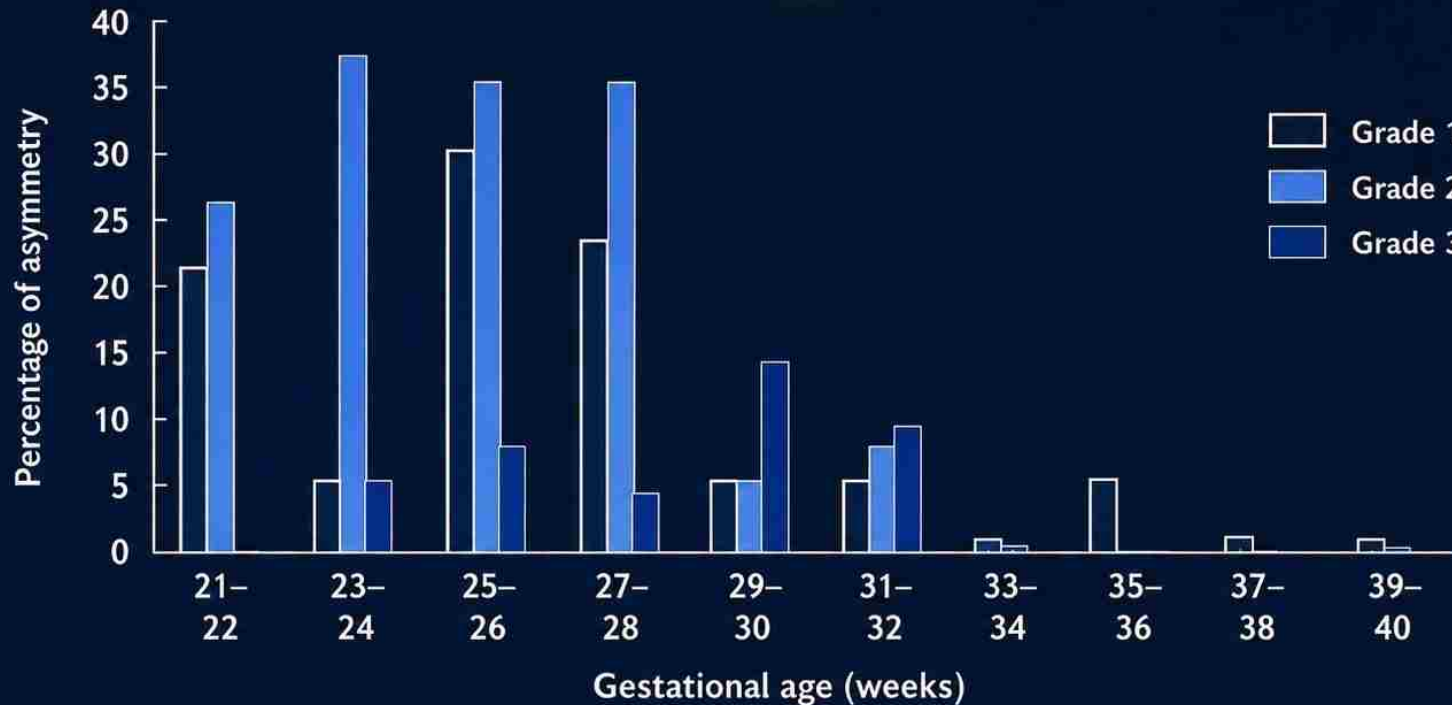


Grade and symmetry of normal fetal cortical development

Longitudinal 2D and 3D ultrasound study



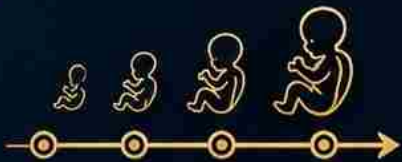
Grade and symmetry of normal fetal cortical development: a longitudinal two- and three-dimensional ultrasound study



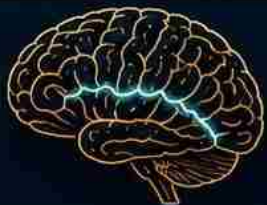
Ultrasound in Obstet & Gyne, Volume: 36, Issue: 6, Pages: 700-708, First published: 24 November 2010, DOI: (10.1002/uog.7705)



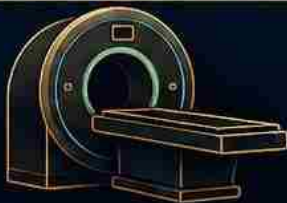Key Take-Home Messages



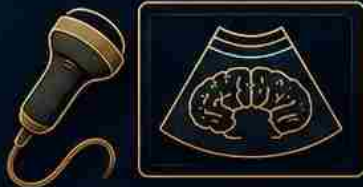Normal sulcation follows predictable gestational milestones



Sylvian fissure maturation is clinically important



MRI improves evaluation of cortical malformations



Serial neurosonography increases diagnostic confidence

